

Harsukh Educational Charitable Society

International Journal of Community Health and Medical Research

Journal home page: www.ijchmr.com

doi: 10.21276/ijchmr

Official Publication of "Harsukh Educational Charitable Society" [Regd.]

ISSN E: 2457-0117 ISSN P: 2581-5040

Index Copernicus value 2016 = 52.13

Original Research

Efficacy of Computed Tomography in detecting cases of Acute Appendicitis

Saket Kumar¹, Syed Gauhar Abbas²

^{1,2}Assistant Professor, Department of Radiodiagnosis, Career Institute of Medical Sciences and Hospital, Lucknow, Uttar Pradesh, India

ABSTRACT

Background: Routine contrast-enhanced computed tomography (CECT) has been described as an accurate diagnostic imaging modality in patients with acute appendicitis. The present study was conducted to assess the efficacy of CT scan in diagnosing cases of acute appendicitis. **Materials & Methods:** The present study was conducted on 250 cases of suspected acute appendicitis. All abdominal CT scans were performed from diaphragm to the symphysis pubis using multi-detector helical CT scanners (MDCT) with intravenous contrast medium. **Results:** Out of 250 patients, males were 150 and females were 100. CT diagnosed 244 correctly. Sensitivity found to be 97.6%, specificity 84%, positive predictive value (PPV) of 76% and negative predictive value (NPV) of 93%. **Conclusion:** The role of CT scan in diagnosing cases of acute appendicitis is increasing. Authors found high sensitivity and specificity of CT scan.

Key words: Acute appendicitis, Computed tomography, Multi-detector

Corresponding author: Dr. Syed Gauhar Abbas, Assistant Professor, Department of Radiodiagnosis, Career Institute of Medical Sciences and Hospital, Lucknow, Uttar Pradesh, India

This article may be cited as: Kumar S, Abbas SG. Efficacy of computed tomography in detecting cases of acute appendicitis. HECS Int J Comm Health Med Res 2018; 4(4):141-143.

INTRODUCTION

Appendicitis should be considered in any person with undiagnosed abdominal pain. The incidence peaks between the ages 15 and 24. The concept that right lower quadrant pain in women of childbearing age is more complex clinical problem than in men and they historically had higher rates of negative laparotomy. Anderson¹ reported decreased diagnostic accuracy for appendicitis among women, particularly in the third decade of life. Clinical diagnosis of appendicitis is usually made on the basis of history, physical examination and laboratory studies but a variety of approaches have been used for diagnosis including ultrasound, helical computerized tomography (CT), clinical scoring systems, and neural network.

It is observed that due to risk-benefit ratio of the surgery, physicians generally accept that about 15 percent of appendectomies will reveal a normal appendix, although this rate varies with the population being considered.² In a healthy young man with right lower quadrant pain, this "negative appendectomy" rate is less than 10 percent, whereas it may reach 20 percent in a young woman due to other pelvic processes that obscure the diagnosis and alter the risk-benefit ratio. Young children and

patients over the age of 65 historically have higher rates of both perforated appendix and negative appendectomy.³

Routine contrast-enhanced computed tomography (CECT) has been described as an accurate diagnostic imaging modality in patients with acute appendicitis. However, most patients with acute appendicitis can be diagnosed by clinical findings and physical exam alone.⁴ The present study was conducted to assess the efficacy of CT scan in diagnosing cases of acute appendicitis.

MATERIALS & METHODS

The present study was conducted in the department of Radiodiagnosis. It comprised of 250 cases of suspected acute appendicitis. All were informed regarding the study and written consent was obtained. Ethical clearance was obtained prior to the study. General information such as name, age, gender etc. was recorded. All abdominal CT scans were performed from diaphragm to the symphysis pubis using multi-detector helical CT scanners (MDCT) with intravenous contrast medium. A number of different CT scanners were used and axial section thickness evolved from 0.625 to 2.5 mm. Two radiologists evaluated the images to overcome bias. Results thus obtained were subjected to statistical analysis. P value less than 0.05 was considered significant.

RESULTS

Table I Distribution of patients

Gender	Number	Percentage
Male	150	60
Female	100	40

Table I shows that out of 250 patients, males were 150 and females were 100.

Graph I: Distribution of patients

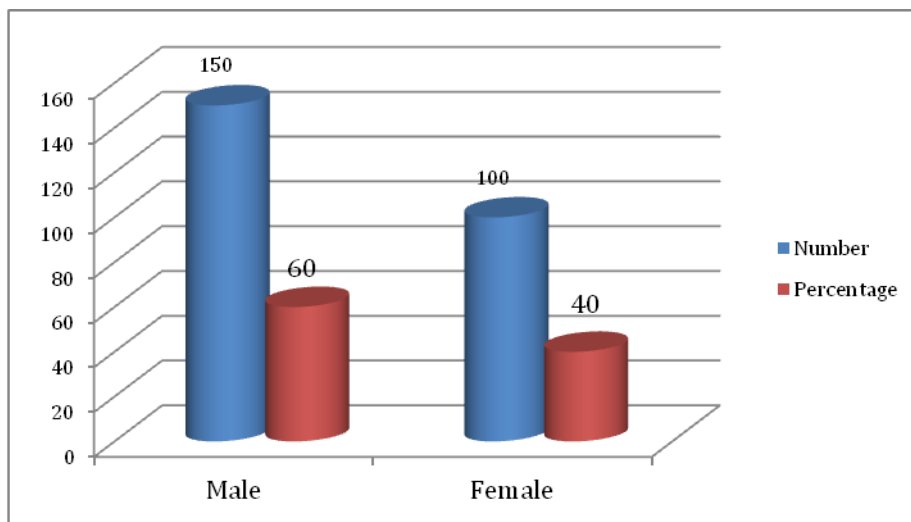
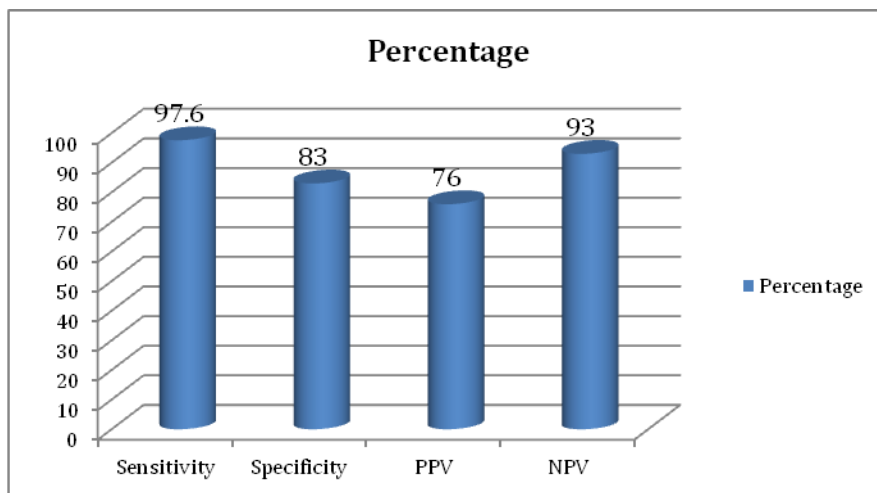


Table II Efficacy of CT scan in diagnosis of acute appendicitis

Total- 250	CT scan
Diagnosed by CT scan	244
Sensitivity	97.6
Specificity	84
PPV	76
NPV	93

Table II shows that out of 250 cases, CT diagnosed 244 correctly. Sensitivity found to be 97.6%, specificity 84%, positive predictive value (PPV) of 76% and negative predictive value (NPV) of 93%.

Graph II: Efficacy of CT scan in diagnosis of acute appendicitis



DISCUSSION

The increased use of CT has been shown to decrease the negative appendectomy rate (NAR) without increase in delayed or false-positive diagnosis. Appendectomy has been the standard treatment for acute appendicitis for over a century. The treatment paradigm of uncomplicated acute appendicitis may be changing as operative treatment may be unnecessary for the majority of uncomplicated appendicitis patients. To optimize and tailor the treatment for acute appendicitis, precise and accurate diagnostic tools such as CT are required.⁵

When using CT to diagnose appendicitis, there are 2 main options: the standard abdominal and pelvic scan and the appendiceal scan with rectal contrast. The former displays classic patterns such as concentric, thickened appendiceal walls; an appendicolith, fat stranding, or other signs of inflammation. A phlegmon, abscess, or free air can also be suggestive of appendicitis. Contrast or air present within the lumen of the appendix virtually excludes the diagnosis of appendicitis. Based on a systematic review of patients with suspected appendicitis, the sensitivity and specificity of a pelvic and abdominal CT scan are 94 percent and 95 percent, respectively. The benefit of a complete abdominal scan is that alternative diagnoses are made in up to 15 percent of patients.⁶ The present study was conducted to assess the efficacy of CT scan in diagnosing cases of acute appendicitis.

In present study, out of 250 patients, males were 150 and females were 100. Stroman et al⁷ conducted a study with 107 patients consisting of 44 males (41%) and 63 females (59%) with a median age of 33 years (range 13 to 89 years) were imaged with CECT to evaluate suspected appendicitis. Of the 107 CECTs performed, 11 false-positive and 3 false-negative readings were identified, resulting in a sensitivity of 92%, specificity of 85%, PPV of 75%, NPV of 95%, and an overall accuracy of 90%. Forty-three patients were imaged with ultrasound and CECT, and CECT had significantly better sensitivity and accuracy (30% versus 92% and 69% versus 88%, $P < 0.01$). With regard to clinical management, 100% (36/36) of patients with appendicitis, and 4.2% (3/71) of patients without appendicitis underwent appendectomy. Therefore, the overall negative appendectomy rate was 7.6% (3/39).

We found that CT diagnosed 244 correctly. Sensitivity found to be 97.6%, specificity 83%, positive predictive value (PPV) of 76% and negative predictive value (NPV) of 93%. Wagner et al⁸ conducted a study in which eighty-eight of the 96 patients (91.6%) with acute appendicitis were correctly diagnosed by CT, 26 of the 28 patients (93%) without acute appendicitis were correctly diagnosed. Prospective interpretation of CT images yielded a sensitivity of 92 per cent and a specificity of 93 per cent for the diagnosis of acute appendicitis. There were eight false-negative scans. Of the total there were 88 true positives, 26 true negatives, 8 false negatives and no false positives.

Lietzen et al⁹ found that out of the 1065 patients, 714 had acute appendicitis and 351 had other or no diagnosis on computed tomography. There were 700 true-positive, 327 true-negative, 14 false-positive, and 24 false-negative cases. The sensitivity and the specificity of computed tomography were 96.7% respectively. The rate of false computed tomography diagnosis was 4.2% for experienced consultant radiologists and 2.2% for inexperienced resident radiologists. Thus, the experience of the radiologist had no effect on the accuracy of computed tomography diagnosis.

CONCLUSION

The role of CT scan in diagnosing cases of acute appendicitis is increasing. Authors found high sensitivity and specificity of CT scan.

REFERENCES

1. Andersson M, Andersson RE: The appendicitis inflammatory response score: A tool for the diagnosis of acute appendicitis that outperforms the Alvarado score. *World J Surg* 2008;32:1843–1849.
2. Hale DA, Molloy M, Pearl RH, et al. Appendectomy: A contemporary appraisal. *Ann Surg* 1997; 225:252-61.
3. Anderson RE, Ilugander A, Thulin AJ. Diagnostic accuracy and perforation rate in appendicitis: association with age and sex of the patient with appendectomy rate. *Eur J Surg* 1992; 158:37-41.
4. Rao PM, Rhea JT, Novelline RA, McCabe CJ, Lawrason JN, Berger DL, et al. Helical CT technique for the diagnosis of appendicitis: prospective evaluation of a focused appendix CT examination. *Radiology* 1997; 202:139-44.
5. Raja AS, Wright C, Sodickson AD et al. Negative appendectomy rate in the era of CT: An 18-year perspective. *Radiology* 2010; 256:460–465.
6. Van Randen A, Bipat S, Zwinderman AH et al. Acute appendicitis: Meta-analysis of diagnostic performance of CT and graded compression US related to prevalence of disease. *Radiology* 2008; 249:97–106.
7. Stroman DL, Bayouth CV, Kuhn JA, Westmoreland M, Jones RC, Fisher TL, McCarty TM. The role of computed tomography in the diagnosis of acute appendicitis. *The American journal of surgery* 1999; 178(6):485-8.
8. Wagner PL, Eachempati SR, Soe K et al. Defining the current negative appendectomy rate: For whom is preoperative computed tomography making an impact? *Surgery* 2008;144:276–282.
9. Lietzen, Raman SS, Osuagwu FC, Kadell B et al. Effect of CT on false positive diagnosis of appendicitis and perforation. *N Engl J Med* 2008; 358:972–973.